

# Association of Hand Grip Strength with Ultrasound-derived Forearm Muscle Thickness and Echo Intensity in Young Indian Adults

R. Aruna<sup>1\*</sup>, Arnel Arputha Sivarajan<sup>2</sup>, Meenakshi Madhumitha<sup>3</sup>, C. J. Vasanth<sup>2</sup>

<sup>1</sup>Department of Physiology, Mahatma Gandhi Medical College and Research Institute, Sri Balaji Vidyapeeth, Puducherry, India, <sup>2</sup>Department of Radiology, Mahatma Gandhi Medical College and Research Institute, Sri Balaji Vidyapeeth, Puducherry, India, <sup>3</sup>BDS Student, Indira Gandhi Institute of Dental Sciences, Sri Balaji Vidyapeeth, Puducherry, India

## Abstract

**Background:** Muscle thickness (MT) quantification, which reflects the muscle function, can be measured using ultrasonography. Echo intensity (EI) quantified from the ultrasonography-derived skeletal muscle images reflects muscle quality. This study aimed to analyze the associations between handgrip strength, ultrasound-measured forearm MT, and EI in healthy young adults. **Methods:** Sixty healthy volunteers between the ages of 18 and 25 years participated in the study. Brightness mode ultrasonography (USG) was done to measure forearm radial and ulna MT. The EI was measured from an ultrasound image as a mean pixel value using a histogram in Adobe Photoshop. Individuals were tested for forearm handgrip strength using hand dynamometry. **Results:** Males had higher forearm MT and handgrip strength compared to females. Handgrip strength had a significant positive correlation with forearm radius, ulna MT ( $r = 0.726, 0.757$  and  $P < 0.01$ ), and forearm circumference ( $r = 0.529$  and  $P < 0.01$ ) and a negatively correlation with subcutaneous fat thickness ( $r = -0.496$  and  $P < 0.01$ ) and EI ( $r = -0.618$  and  $P < 0.01$ ). Linear regression showed a significant correlation between MT, circumference, and EI with handgrip strength ( $r = 0.825$  and  $P < 0.001$ ). After adjustment for the other two parameters, the forearm MT correlated positively and EI negatively with handgrip strength. **Conclusion:** USG can be more easily used than other imaging methods in research and clinical setting as it is nonhazardous, less expensive, versatile, and provides results faster. Thus, USG measurements in skeletal muscle are useful for measuring MT and subcutaneous fat thickness. EI measurement can be a convenient and noninvasive method for assessing muscle quality.

**Keywords:** Echo intensity, muscle quality, muscle strength, muscle thickness, ultrasound imaging

## INTRODUCTION

Ultrasonography (USG) is an important imaging method for studying the musculoskeletal system.<sup>[1]</sup> A normal and healthy muscle in ultrasound looks black and has less echo intensity (EI). The appearance of the bone is evident as it has an anechoic bone shadow, and the rim has a high EI which can be easily viewed in ultrasound images for measuring the muscle thickness (MT).<sup>[2]</sup> MT is an important indicator and factor in determining muscle strength.<sup>[3]</sup> There have been studies on the association between MT and other parameters, such as the level of physical activity, age, muscle stiffness, and response to exercise.<sup>[4]</sup> The cross-sectional area of muscle correlates with the maximum force of contraction.<sup>[5]</sup> MT and

cross-sectional areas of the muscles are important factors in determining muscle strength.<sup>[4]</sup> The rate of muscle strength decline in physiological aging is three times earlier than the muscle mass reduction, indicating a decrease in muscle quality.<sup>[6]</sup> An association between skeletal muscle quality and muscle strength is still not clear in young adults. Studies suggest that intramuscular fat accumulation in skeletal muscle may be associated with decreased muscle strength, function, and muscle quality.<sup>[7]</sup> EI of the skeletal muscle obtained from

**Address for correspondence:** Dr. R. Aruna,

Department of Physiology, Mahatma Gandhi Medical College and Research Institute, Sri Balaji Vidyapeeth, Puducherry, India.

E-mail: arunaraju10@gmail.com

Received: 17-03-2022 Revised: 29-04-2022 Accepted: 27-07-2022 Available Online: 07-10-2022

### Access this article online

#### Quick Response Code:



**Website:**  
<https://journals.lww.com/jmut>

**DOI:**  
10.4103/jmu.jmu\_28\_22

This is an open access journal, and articles are distributed under the terms of the Creative Commons Attribution-NonCommercial-ShareAlike 4.0 License, which allows others to remix, tweak, and build upon the work non-commercially, as long as appropriate credit is given and the new creations are licensed under the identical terms.

**For reprints contact:** WKHLRPMedknow\_reprints@wolterskluwer.com

**How to cite this article:** Aruna R, Sivarajan AA, Madhumitha M, Vasanth CJ. Association of hand grip strength with Ultrasound-derived forearm muscle thickness and echo intensity in young Indian adults. J Med Ultrasound 2023;31:206-10.

USG-derived images has been used as an indicator of muscle quality.<sup>[8]</sup> Ultrasound echogenicity is due to the reflection and absorption of ultrasound waves by the underlying tissues, and this can be measured using computer-aided grayscale analysis from the ultrasound-derived image.<sup>[9]</sup> Normal skeletal muscle has contractile proteins and noncontractile elements, such as intramyocellular adipocytes and fibrous tissue.<sup>[10]</sup> Healthy skeletal muscle appears black, having “low echogenicity,” indicating high muscle quality. Intramyocellular fat, fibrous tissue and adipose tissue appears white having “high echogenicity” indicative of low muscle quality.<sup>[2]</sup>

Previous studies have assessed the association between MT, muscle quality, and muscle strength; they are still incompletely characterized, especially in young adults. There is a lack of data assessing muscle quality and quantifying MT in the upper limb using ultrasound in healthy Indians. This calls for studies looking at both muscle quantity (thickness) and quality (EI) simultaneously in the healthy Indian population; this will improve our understanding, and more evidence is necessary to explore the clinical implications of assessing muscle quantity and quality from ultrasound images. This will be the first attempt of its kind in the Indian population to assess skeletal muscle strength and quantify MT and muscle quality of forearm muscle using ultrasound. The purpose of the present study was to investigate the associations between handgrip strength and ultrasound-measured forearm MT and EI, in healthy young adults.

This study hypothesizes that USG may be useful in assessing both the quantity and quality of skeletal muscle in young adults.

## MATERIALS AND METHODS

### Study design

This was a cross-sectional study.

### Study participants and sampling

Sixty healthy volunteers between the ages of 18 and 25 years of both genders who consented to the study were recruited by a convenient random sampling technique. Individuals with muscular dystrophy, joint injuries, or surgeries to the wrist were excluded from the study.

### Sample size

The sample size was calculated using a standard deviation of ulna MT from a previous study by Abe *et al.*<sup>[11]</sup> with a 95% confidence interval. The required sample size was 59, rounding up to 60.

### Ethical considerations

This study was approved by the Institutional Human Ethics committee (IHEC No: IGIDSIEC2020NRP50UGMMPHY). Helsinki and the National Ethical Guidelines for Biomedical and Health Research 2017 declaration by the Indian Council of Medical Research were followed throughout the study.

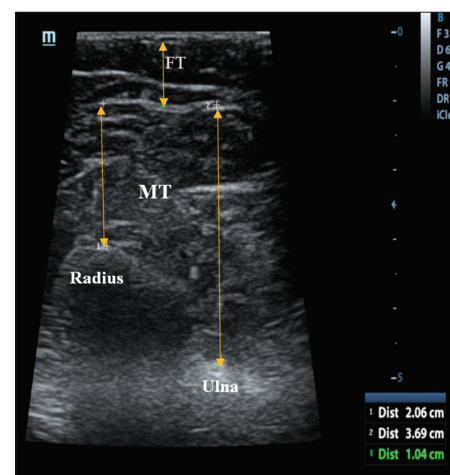
Height, weight, and forearm circumference were measured. Height and weight were used for calculating body mass index ( $\text{kg}/\text{m}^2$ ). The distance between radial styloid process

and radius head on the lateral surface was measured, and the forearm circumference was marked at 30% proximal site between this distance and measured using a measuring tape this represents maximum forearm circumference.<sup>[11,12]</sup>

Individuals were tested for handgrip strength using hand dynamometry (Camry electronic handgrip dynamometer). The participant was asked to stand, extend the forelimb, and hold the handgrip dynamometer on the dominant hand as tight as possible for 5 s, and the maximum value was taken as the grip strength. Three trials were given for each participant, with the rest in between the trials, and the best of the three trials was taken as the handgrip strength for calculation.

USG was done using a real-time brightness mode to measure MT in the dominant hand during the resting state. Water-soluble and Hypoallergic ultrasound transmission gel was used in the 7.5-MHz transducer scanning head and placed at the marked site of forearm circumference at a 30% proximal site between the radial styloid process and the radius head and muscle images were captured. MT was measured as the perpendicular distance between the subcutaneous tissue–muscle interface and muscle–bone interface from the frozen ultrasound image using an electric caliper present in the USG device. In the lateral forearm, two MTs were measured as the perpendicular distances between the subcutaneous tissue–forearm muscle interface and forearm muscle–radial bone interface for forearm–radius MT and subcutaneous tissue–forearm muscle interface and forearm muscle–ulna bone interface for forearm–ulna MT as shown in Figure 1.<sup>[12]</sup> To measure the reliability of the MT measurement, two independent observers measured MT, and the mean value obtained from the two measurements was used for the analysis. Intraclass correlation coefficient (ICC) for checking the similarity and coefficient of variation (CV) for checking the variability between the two independent observers were calculated.

EI is the average pixel intensity of the muscle in the ultrasound-derived image. The value of EI was calculated as the mean value in the histogram of Adobe Photoshop. A region



**Figure 1:** Forearm muscle and subcutaneous fat thickness measurement in ultrasound image. FT: subcutaneous fat thickness, MT: Muscle thickness

of interest was selected by including only muscle without any surrounding structure, such as the bone and fascia. The EI value of the ultrasound image in the histogram of Adobe Photoshop was expressed between 0 and 255a.u.<sup>[13]</sup>

Statistical analysis was done using SPSS 17.0 (IBM Corp., Armonk, NY, USA) software. The Shapiro–Wilk test was done to check for data normality. All normally distributed data were represented as mean and standard deviation. ICC and CV were calculated to compare MT derived by two independent observers. Gender differences were determined using unpaired Student's *t*-tests. Pearson correlation coefficient was done to find the association between handgrip strength, MT, subcutaneous thickness, and forearm circumference. Linear regression was used to find the individual association between MTs of the forearm, forearm circumference, EI, and handgrip strength. Partial correlation coefficients were used to find the correlation between the MTs of the forearm, forearm circumference, EI, and handgrip strength after controlling for the effect of other variables.

## RESULTS

Characteristic of the study population are shown in Table 1. Age was similar for both genders, and height and weight were higher in males than in females. Forearm MT and handgrip strength were greater in males compared to females. Handgrip strength showed a positive correlation with both forearm radius MT ( $r = 0.730$  and  $P < 0.001$ ), and ulna MT ( $r = 0.766$  and  $P < 0.001$ ) as shown in Figure 2, and also with forearm circumference ( $r = 0.547$  and  $P < 0.001$ ) and it was negatively correlated with subcutaneous fat thickness ( $r = -0.501$  and  $P < 0.001$ ) and EI ( $r = -0.618$  and  $P < 0.001$ ) as shown in Figure 3. Linear regression showed there is a significant correlation of parameters with handgrip strength ( $r = 0.825$  and  $P < 0.001$ ). After adjustment for the other two parameters, the forearm MT correlated positively and EI negatively with handgrip strength as depicted in Table 2. To assess test–retest reliability, ICC and CV were done to compare MT derived by two independent observers. ICC and CV were 0.910 and 1.29% for forearm radial MT, and ICC and CV were 0.970 and 1.24% for forearm ulna MT, respectively.

## DISCUSSION

This study indicates a significant correlation between forearm radial MT, forearm ulna MT and handgrip strength, and the forearm circumference was associated with handgrip strength. Subcutaneous fat thickness in our study showed a negative correlation to handgrip strength in a young healthy adult.

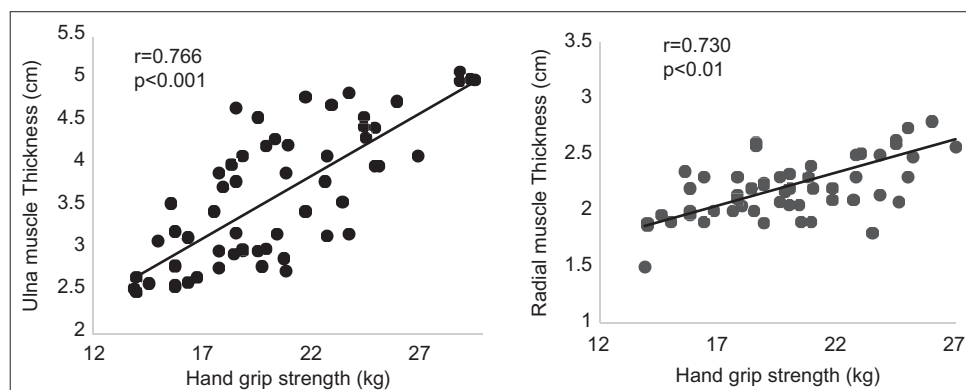
The force of contraction in handgrip strength greatly depends on the size of forearm muscles. A study by Abe *et al.* has shown a positive association between the forearm handgrip strength and MT measurement done using ultrasonography; our study results are similar to his study in young adults in the age group of 18 and 34 years, where he has shown that the correlations between forearm radial and ulna MTs and handgrip strength were ( $r = 0.576, 0.733$ ) in males and ( $r = 0.732, 0.814$ ) in females,<sup>[11]</sup> and also in a study by Morimoto *et al.* in 30 adult young male reported that the correlations between forearm radial and ulna MTs and handgrip strength were ( $r = 0.705, 0.661$ ),<sup>[14]</sup> which are similar to our study result ( $r = 0.726, 0.757$ ).

For measuring subcutaneous fat skinfold thickness, methods such as skinfold caliper, or other medical imaging methods such as magnetic resonance imaging (MRI), computed

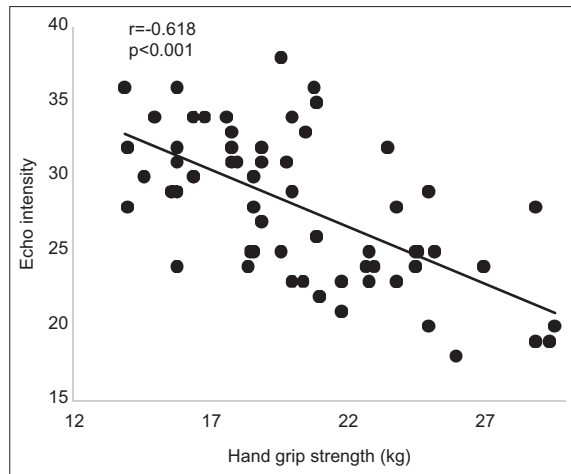
**Table 1: Characteristics of the study population**

Parameter	Male	Female	P
Age (years)	21.33±2.03	20.96±2.4	0.532
Height (cm)	170±3.3	157.9±5.4**	<0.001
Weight (kg)	71.1±7.4	57.9±6.4**	<0.001
BMI (kg/m <sup>2</sup> )	24.5±2.4	23.2±2.2*	0.027
Waist circumference (cm)	81.56±8.0	75.7±8.5*	0.009
Forearm circumference (cm)	25.7±1.92	22.7±2.27**	<0.001
Handgrip strength (kg)	21.92±4	18.82±3.5*	0.003
Forearm radial muscle thickness (cm)	2.35±0.36	2.12±0.29*	0.010
Forearm ulna muscle thickness (cm)	4.19±0.60	3.03±0.47*	<0.001
Subcutaneous fat thickness (mm)	4.8±0.40	5.4±0.26**	<0.001
Echo intensity	25.96±5.2	29.9±3.91	0.002

BMI: Body mass index. \* $P < 0.05$ , \*\* $P < 0.01$



**Figure 2:** Association between handgrip strength and forearm ulna and radial MT. MT: Muscle thickness



**Figure 3:** Association between handgrip strength and echo intensity

tomography (CT), and USG are used.<sup>[15]</sup> USG measured subcutaneous fat thickness reliably correlates with other measurement techniques, such as CT,<sup>[16]</sup> MRI,<sup>[17]</sup> and Dual energy X-ray absorptiometry (DEXA).<sup>[18]</sup> Subcutaneous fat thickness measurement by the USG imaging technique provides accurate and reliable measures.<sup>[19]</sup> Bellisari *et al.* in their study have reported lesser inter- and intraindividual variation in subcutaneous fat thickness measurement by USG.<sup>[20]</sup> In the present study, the subcutaneous fat thickness of the forearm was negatively correlated with handgrip. Similarly, Hobson-Webb *et al.* in their study also reported a significant negative correlation between vastus lateralis subcutaneous fat thickness and handgrip strength ( $r = 0.64$ ,  $P = 0.009$ ),<sup>[21]</sup> indicating muscle strength decreased with an increase in subcutaneous fat thickness. This may be due to handgrip strength being mainly contributed by the muscles of the forearm, and the strength could have been affected by the higher subcutaneous fat present.

Forearm circumference is an index of hand grip strength as it is associated with muscle mass, and it was reported to be an important predictor of hand grip strength in many studies.<sup>[22]</sup> Similar to the present study, Abe *et al.* in young adults have shown that forearm circumference significantly correlated with handgrip strength in both males and females ( $r = 0.623$ ,  $0.653$ ). They also has reported a significant correlation between forearm MT and hand grip strength.<sup>[11]</sup> Abe *et al.* in elderly women have reported forearm circumference was not significantly correlated with grip strength and attributed it to increased subcutaneous fat thickness. However, the relationship becomes statistically significant after adjusting for subcutaneous fat thickness measured by ultrasound.<sup>[12]</sup> Forearm circumference includes even the skin and underlying subcutaneous fat, so it is necessary to consider subcutaneous thickness when forearm circumference is used for predicting hand grip strength. With the application of ultrasound examination, measurement of the thickness of muscle, subcutaneous fat, and skin is feasible and reliable.

The accumulation of fat in the muscles (intramyocellular fat), i.e. changes in muscle quality, can be measured using

**Table 2: Partial regression coefficients between handgrip strength and forearm muscle thickness, forearm circumference, and echo intensity**

Parameter	$\beta$	$P$	Partial correlation
Forearm radial and ulna muscle thickness (cm)	0.44	0.002	0.395
Forearm circumference (cm)	0.27	0.010	0.337
Echo intensity	-0.30	0.013	-0.325
$R$	$R^2$	SEE	Significance
0.825	0.685	2.35	<0.01

SEE: Standard error of estimation

CT imaging and MRI. Goodpaster *et al.* disclosed that the attenuation coefficient of CT image was decreased due to fat accumulation in the muscle.<sup>[23]</sup> On the other hand, the degree of intramyocellular adipose tissue infiltration could be evaluated with MRI by measuring the lipid signal intensity.<sup>[24]</sup> Furthermore, studies have shown the correlation between EI and CT or MRI measurements for the degree of fat infiltration inside muscles. Watanabe *et al.* showed a positive correlation between CT value of fat measurement and EI in thigh muscle ( $r = 0.524$  and  $P < 0.01$ ).<sup>[25]</sup> A study by Young *et al.* showed that there was a strong correlation between MRI-measured fat percent and muscle EI ( $r = 0.91$  and  $P < 0.01$ ) in the rectus femoris.<sup>[26]</sup> Muscle quality assessed by muscle biopsy suggests that echogenicity is more strongly associated with intramuscular fat infiltration rather than fibrosis.<sup>[27]</sup> Thus, EI measurements using USG-derived images can be used as a measure of muscle quality. This technique is cheaper, noninvasive, readily available, and safer than that other imaging techniques such as CT and MRI in indicating fat infiltration in the muscle.

In a study by Strasser *et al.* on the elderly, there was no significant association between EI and muscle strength.<sup>[28]</sup> The present study showed a negative association between EI and forearm grip strength. In line with our study, Stock *et al.* showed that the EI was negatively correlated with thigh muscle strength ( $r = -0.524$  and  $P < 0.01$ ) in children in the age Groups 11 and 14.<sup>[29]</sup> A study by Watanabe *et al.* in older adults also showed that the EI had a negative correlation with muscle strength ( $r = -0.333$  and  $P < 0.01$ ), so this implies EI reflects muscle quality and function can be assessed.<sup>[13]</sup> The accumulation of fat and connective tissue in skeletal muscle could be indicated by higher echogenicity and could have resulted in decreased muscle quality leading to impaired muscle strength.

### Limitation

Although the study established the significant relationship between MT and forearm muscle strength, a lesser number of study participants and limited region might have led to some degree of result bias. A large number of participants with a wide age range are needed to apply this to the entire population. There is no standard value for the EI, so it is not possible to compare our study's EI values with those obtained



from other studies using different USG. Therefore, there is a need for describing a standard method for reporting the EI of skeletal muscle.

## CONCLUSION

Our study indicates USG-measured radial and ulna MT positively and subcutaneous fat thickness is negatively associated with muscle strength. Our study suggests that USG-measured MT can be used for assessing muscle function in the forearm. EI assessed from USG images is an indicator of muscle quality.

## Financial support and sponsorship

Nil.

## Conflicts of interest

There are no conflicts of interest.

## REFERENCES

- Han P, Chen Y, Ao L, Xie G, Li H, Wang L, *et al.* Automatic thickness estimation for skeletal muscle in ultrasonography: Evaluation of two enhancement methods. *Biomed Eng Online* 2013;12:6.
- Pillen S, van Alfen N. Skeletal muscle ultrasound. *Neurol Res* 2011;33:1016-24.
- Muraki S, Fukumoto K, Fukuda O. Prediction of the muscle strength by the muscle thickness and hardness using ultrasound muscle hardness meter. *Springerplus* 2013;2:457.
- Peterson CM, Johannsen DL, Ravussin E. Skeletal muscle mitochondria and aging: A review. *J Aging Res* 2012;2012:194821.
- Maughan RJ, Watson JS, Weir J. Strength and cross-sectional area of human skeletal muscle. *J Physiol* 1983;338:37-49.
- Mitchell WK, Williams J, Atherton P, Larvin M, Lund J, Narici M. Sarcopenia, dynapenia, and the impact of advancing age on human skeletal muscle size and strength; a quantitative review. *Front Physiol* 2012;3:260.
- Rahemi H, Nigam N, Wakeling JM. The effect of intramuscular fat on skeletal muscle mechanics: Implications for the elderly and obese. *J R Soc Interface* 2015;12:20150365.
- Stock MS, Thompson BJ. Echo intensity as an indicator of skeletal muscle quality: Applications, methodology, and future directions. *Eur J Appl Physiol* 2021;121:369-80.
- Stringer HJ, Wilson D. The role of ultrasound as a diagnostic tool for sarcopenia. *J Frailty Aging* 2018;7:258-61.
- Correa-de-Araujo R, Harris-Love MO, Miljkovic I, Fragala MS, Anthony BW, Manini TM. The need for standardized assessment of muscle quality in skeletal muscle function deficit and other aging-related muscle dysfunctions: A symposium report. *Front Physiol* 2017;8:87.
- Abe T, Counts BR, Barnett BE, Dankel SJ, Lee K, Loenneke JP. Associations between handgrip strength and ultrasound-measured muscle thickness of the hand and forearm in young men and women. *Ultrasound Med Biol* 2015;41:2125-30.
- Abe T, Thiebaud RS, Loenneke JP, Ogawa M, Mitsukawa N. Association between forearm muscle thickness and age-related loss of skeletal muscle mass, handgrip and knee extension strength and walking performance in old men and women: A pilot study. *Ultrasound Med Biol* 2014;40:2069-75.
- Watanabe Y, Yamada Y, Fukumoto Y, Ishihara T, Yokoyama K, Yoshida T, *et al.* Echo intensity obtained from ultrasonography images reflecting muscle strength in elderly men. *Clin Interv Aging* 2013;8:993-8.
- Morimoto A, Suga T, Tottori N, Wachi M, Misaki J, Tsuchikane R, *et al.* Association between hand muscle thickness and whole-body skeletal muscle mass in healthy adults: A pilot study. *J Phys Ther Sci* 2017;29:1644-8.
- Störchle P, Müller W, Sengeis M, Lackner S, Holasek S, Fürhapter-Rieger A. Measurement of mean subcutaneous fat thickness: Eight standardised ultrasound sites compared to 216 randomly selected sites. *Sci Rep* 2018;8:16268.
- Mook-Kanamori DO, Holzhauer S, Hollestein LM, Durmus B, Manniesing R, Koek M, *et al.* Abdominal fat in children measured by ultrasound and computed tomography. *Ultrasound Med Biol* 2009;35:1938-46.
- Koda M, Senda M, Kamba M, Kimura K, Murawaki Y. Sonographic subcutaneous and visceral fat indices represent the distribution of body fat volume. *Abdom Imaging* 2007;32:387-92.
- Leahy S, Toomey C, McCreesh K, O'Neill C, Jakeman P. Ultrasound measurement of subcutaneous adipose tissue thickness accurately predicts total and segmental body fat of young adults. *Ultrasound Med Biol* 2012;38:28-34.
- Toomey C, McCreesh K, Leahy S, Jakeman P. Technical considerations for accurate measurement of subcutaneous adipose tissue thickness using B-mode ultrasound. *Ultrasound* 2011;19:91-6.
- Bellisari A, Roche AF, Siervogel RM. Reliability of B-mode ultrasonic measurements of subcutaneous adipose tissue and intra-abdominal depth: Comparisons with skinfold thicknesses. *Int J Obes Relat Metab Disord* 1993;17:475-80.
- Hobson-Webb LD, Zwelling PJ, Raja SS, Pifer AN, Kishnani PS. Quantitative muscle ultrasound and electrical impedance myography in late onset Pompe disease: A pilot study of reliability, longitudinal change and correlation with function. *Mol Genet Metab Rep* 2021;28:100785.
- Alahmari KA, Silvian SP, Reddy RS, Kakaraparthi VN, Ahmad I, Alam MM. Hand grip strength determination for healthy males in Saudi Arabia: A study of the relationship with age, body mass index, hand length and forearm circumference using a hand-held dynamometer. *J Int Med Res* 2017;45:540-8.
- Goodpaster BH, Kelley DE, Thaete FL, He J, Ross R. Skeletal muscle attenuation determined by computed tomography is associated with skeletal muscle lipid content. *J Appl Physiol* (1985) 2000;89:104-10.
- Goodpaster BH, Stenger VA, Boada F, McKolanis T, Davis D, Ross R, *et al.* Skeletal muscle lipid concentration quantified by magnetic resonance imaging. *Am J Clin Nutr* 2004;79:748-54.
- Watanabe Y, Ikenaga M, Yoshimura E, Yamada Y, Kimura M. Association between echo intensity and attenuation of skeletal muscle in young and older adults: A comparison between ultrasonography and computed tomography. *Clin Interv Aging* 2018;13:1871-8.
- Young HJ, Jenkins NT, Zhao Q, McCully KK. Measurement of intramuscular fat by muscle echo intensity. *Muscle Nerve* 2015;52:963-71.
- Reimers K, Reimers CD, Wagner S, Paetzke I, Pongratz DE. Skeletal muscle sonography: A correlative study of echogenicity and morphology. *J Ultrasound Med* 1993;12:73-7.
- Strasser EM, Draskovits T, Prashchak M, Quittan M, Graf A. Association between ultrasound measurements of muscle thickness, pennation angle, echogenicity and skeletal muscle strength in the elderly. *Age (Dordr)* 2013;35:2377-88.
- Stock MS, Mota JA, Hernandez JM, Thompson BJ. Echo intensity and muscle thickness as predictors of athleticism and isometric strength in middle-school boys. *Muscle Nerve* 2017;55:685-92.